

Research Article

The Relationship Between Fragmented QRS and Diastolic Parameters in Coronary Artery Disease Patients with Noncritical Lesions

 Ferdi Sezer,  Murat Meric,  Serkan Yuksel,  Murat Akcay,  Okan Gulel

Department of Cardiology, Ondokuz Mayıs University Faculty of Medicine, Samsun, Turkey

Abstract

Objectives: Previous studies have shown fragmented QRS (fQRS) in electrocardiography (ECG) to be associated with regional myocardial scars. We sought in this study to evaluate the effect of fQRS on diastolic parameters using conventional and tissue Doppler methods in patients with normal systolic function who have noncritical stenosis demonstrated via coronary angiography.

Methods: This study includes 60 patients with fQRS on a surface ECG and 40 control patients with similar demographic characteristics but without fQRS on a surface ECG. Diastolic parameters were compared between the two groups using the conventional and tissue Doppler methods. Fragmented QRS was defined as the presence of a second R (R') wave, notching of the R or S wave, or fragmentation of the R wave (more than one R') in at least two consecutive leads compatible with epicardial coronary arteries.

Results: Compared with conventional echocardiography, regional tissue Doppler parameters revealed significant differences in patients with fQRS compared to those without fQRS: e' (tissue Doppler early diastolic velocity) and e'/a' (the ratio of early to late diastolic velocities) from tissue Doppler echocardiography parameters were found to be lower in patients with fQRS compared with the control group ($p < 0.05$).

Conclusion: According to the results of our study, the presence of fQRS on a surface ECG is associated with deterioration of left ventricular diastolic function, both regionally and globally, and this deterioration is more evident at the tissue level. In conclusion, fQRS on a surface ECG can be an early predictor of diastolic dysfunction.

Keywords: Coronary artery disease, diastolic dysfunction, fragmented QRS

Cite This Article: Sezer F, Meric M, Yuksel S, Akcay M, Gulel O. The Relationship Between Fragmented QRS and Diastolic Parameters in Coronary Artery Disease Patients with Noncritical Lesions. *ejmi*. 2018; 2(4): 213-219

Coronary artery disease (CAD) is a significant cause of morbidity and mortality around the world. With regard to coronary artery disease, changes in left ventricular diastolic functions are associated with the effects of myocardial ischemia and fibrosis on diastolic hemodynamics. It has been reported that significant left ventricular diastolic dysfunction can develop even when silent myocardial ischemia is present.^[1,2] The diastolic relaxations of ventricles can deteriorate selectively, independent of systolic functions, due to relaxation asynchronization between ischemic and normal myocardial segments in CAD patients.

Additionally, local fibrotic scarring can form even though microemboli, micro-infarct areas, and systolic functions are not affected by non-critical atherosclerotic stenoses.^[3]

Previous studies have indicated a relationship between fibrotic scarring and the presence of fragmented QRS (fQRS), which is an indirect symptom of subclinical myocardial damage and which can be observed via resting surface electrocardiography (ECG).^[4-6] fQRS is a depolarization anomaly that indicates conduction delay on standard surface ECGs with 12 derivations. The formation of fQRS on an ECG is expressed via inhomogeneous activation of the ven-

Address for correspondence: Murat Meric, MD. Ondokuz Mayıs Üniversitesi Tıp Fakültesi, Kardiyoloji Anabilim Dalı, Samsun, Turkey

Phone: +90 532 685 34 60 **E-mail:** drmeric@hotmail.com

Submitted Date: October 10, 2018 **Accepted Date:** November 06, 2018 **Available Online Date:** November 29, 2018

©Copyright 2018 by Eurasian Journal of Medicine and Investigation - Available online at www.ejmi.org



tricle due to myocardial fibrotic scar tissue.^[4-6] The presence of fQRS on an ECG is a prominent indicator of myocardial fibrosis and scarring, and CAD is a symptom of poor prognosis in cardiovascular diseases, including heart failure and arrhythmogenic syndromes.^[7-14]

In this study, we excluded to a great extent the risk factors that create cardiac diastolic dysfunction and aimed to examine the relationship between diastolic cardiac parameters and the presence of fQRS in coronary artery patients who have non-critical stenosis with normal systolic function proven by coronary angiography.

Methods

A total of one hundred patients who applied to Ondokuz Mayıs University, Faculty of Medicine, Cardiology Polyclinics were included in this study. These patients were diagnosed as stable angina pectoris and were planned to undergo coronary angiography due to ischemia in the treadmill effort test or myocardial perfusion scintigraphy. Patients with coronary plaques causing less than 50% stenosis in lumen diameter or less than 70% stenosis in lumen area at coronary angiography were admitted to the study. Among these patients, 60 of them had surface ECG with fQRS and 40 of them with similar demographic characteristics had no fQRS on surface ECG. The patients were informed about the nature of the study and written consent was obtained from each participant. The study was approved by the local ethical committee.

Patients excluded from the study included those who had no sinus rhythm (atrial fibrillation, atrial flutter, etc.), who had valvular heart disease, showed pathological Q wave in their ECG, had incomplete or complete bundle branch block, pacemaker rhythm, or tachy-brady-arrhythmia, were over 65, had angiographic occlusive ischemic coronary artery disease (stenosis over 50% by diameter or 70% or more by area), had ≥ 30 kg/m² body mass index (BMI), were diagnosed with diabetes mellitus, had congenital heart disease, were diagnosed to have cardiomyopathy, or who had systolic dysfunction. The patients' age, sex, waist circumference, smoking status, blood pressure, BMI, and heart rate were recorded. Glucose, triglyceride, total cholesterol, HDL-C and low-density lipoprotein cholesterol concentrations, and creatinine values were measured after a 12-h fast.

Electrocardiography

The 12-lead ECG analysis (GE, Marquette, WI; model Mac 5000; filter range, 0.15 to 100 Hz; AC filter, 60 Hz, 25 mm/s, 10 mm/mV) was performed by two independent readers blinded to echocardiography results, cardiac catheterization findings, and follow-up data. fQRS is defined as

the varying RSR' pattern content of QRS (<120 ms) morphologies in two derivations that follow each other in the inferior area (D II, D III, avF), anterior area (V1-5), and lateral area (DI-avL, V6), which correspond to the areas fed by the major coronary arteries. These varying morphologies are accepted as an additional R wave (R') or notching at the end of the R or S wave or the presence of more than one R' wave.^[15] ECGs were assessed by two cardiologists who did not know the results of echocardiography. There was a 99.5% concordance between the cardiologists with regard to fQRS in ECGs. The presence of fQRS in more than two consecutive derivations was evaluated as 'apparent fQRS'.

Coronary Angiography

The left and right coronary imaging of patients was carried out via the femoral artery and left radial artery using the standard Judkin's technique and a Siemens Axiom Artis device (Siemens Healthcare, Erlangen, Germany) in the angiography and catheterization lab of our clinic. Prior to angiography, informed consent forms were obtained from patients confirming that the patients acknowledged and consented to the process. A quantitative coronary angiography (QCA) system was used to determine the presence of coronary lesions and measure any such lesions, and reference vein diameter, coronary stenosis diameter, percentage of area and length of stenosis were calculated.^[16] Lesions that did not cause angiographic occlusive ischemic stenosis or that were less than 50% of the vein diameter or less than 70% as area ratio were assessed as noncritical, while lesions that caused the initial disorder or less than 25% stenosis in vein structure without ventricular wall movement disorder were evaluated as plaque lesions.

Echocardiography

All echocardiography examinations were performed with a Vivid Seven Echocardiography machine (GE Vingmed Ultrasound A/S, Horten, Norway) equipped with a 2.5 MHz probe. All echocardiography measurements were performed according to the guidelines. Echocardiography examinations were performed within 24 hours after the coronary angiography.

Left ventricular (LV) dimensions and wall thicknesses were measured by the M-mode in the parasternal long-axis view. LV end-diastolic volume, end-systolic volume, and ejection fraction were obtained using Simpson's biplane method of discs in the apical 4-chamber and 2-chamber views.

Mitral inflow velocities were measured using conventional pulsed-wave Doppler by positioning sample volume at the level of the tips of mitral leaflets in the apical 4-chamber view. The Doppler beam was aligned parallel to the direction of flow. Peak early (E) and late (A) diastolic velocities

and E/A ratios were measured. A mean of three consecutive cardiac cycles was used for the calculations of all echo-Doppler parameters. Mitral pulsed-wave Doppler time intervals were measured from mitral inflow and left ventricular outflow Doppler tracings, as described by Tei and colleagues.^[17] Three consecutive beats were measured and averaged for each parameter. Isovolumic relaxation time (IVRT) was measured from the closure of the aortic valve to the opening of the mitral valve. Isovolumic contraction time (IVCT) was measured from the closure of the mitral valve to the opening of the aortic valve. Ejection time (ET) was measured from the opening to the closing of the aortic valve on the LV outflow velocity profile. Myocardial performance index (MPI) was calculated using these mean values and the (IVRT+IVCT)/ET formula.

Pulsed-wave tissue Doppler imaging was achieved using a low wall filter setting, a small sample volume, and optimal gain. The angle between the Doppler beam and the longitudinal motion of the region of interest was also minimized. For the tissue Doppler image of the mitral annular motion, sample volumes were placed at the septal and lateral mitral annuli in the apical 4-chamber view and at the anterior and inferior mitral annuli in the apical 2-chamber view. Peak systolic (*s'*), peak early diastolic (*e'*), and peak late diastolic (*a'*) velocities were measured. Mean values of the same parameters were calculated for the mitral annuli.

Statistical Analysis

Statistical analyses were performed using SPSS for Windows version 15.0 (SPSS Inc., Chicago, IL). The obtained data were presented in numbers, as average±standard deviation (SD) and percentage. The normality of the distribution of the parameters was analyzed using the Kolmogorov–Smirnov test. In the comparison of the groups, student t-tests and chi-squared tests were used to analyze data that was normally distributed, while the Mann Whitney U-test was used for data that did not comply with normal distribution. The chi-squared test was used for intergroup comparisons in terms of categorical variables. The significance level was set at $p<0.05$.

Results

Clinical characteristics, including age, gender, heart rate, BMI, and blood pressure levels were similar in all the groups. The clinical characteristics of the two groups are shown in Table 1. Compared with conventional echocardiography, regional tissue Doppler parameters revealed significant differences in patients with fQRS. Values of *e'* (tissue Doppler early diastolic velocity) and *e'/a'* (ratio of early and late diastolic velocities) from tissue Doppler echocardiography parameters were found to be lower in patients with fQRS

compared with the control group ($p<0.05$; Table 2).

There was no statistically significant difference between the groups in terms of myocardial performance indexes (MPIs) ($p>0.05$). The groups did not demonstrate a significant difference in terms of transmitral E, A, or tissue Doppler *a'* parameters ($p>0.05$). There was an apparent statistical difference between the groups in tissue Doppler *e'*, E/*e'* (average), and *e'/a'* (average) measurements ($p<0.05$).

The diameter measurements of the left ventricle diastole end were significantly high in fQRS cases compared to the control group ($p<0.05$). The diameter measurements of the left atrium were significantly high in fQRS cases compared to those in the control group ($p<0.05$).

MPI, DT, and IVRT all showed deterioration with fQRS, but no statistical significance was found. The E/A ($p<0.05$) ratio among the mitral flow parameters used to evaluate left ventricular diastolic dysfunction with conventional Doppler echocardiography, average *e'* ($p<0.05$) among the tissue Doppler parameters, average *e'/a'* ($p<0.05$) ratios were found to be lower in fQRS patients compared to the control group.

It was found that there was an increase in favor of fQRS in (E/*e'*<8; E/*e'*=8–15; E/*e'*>15); E/*e'* (average) (8<E/Em<15) when all the patients were distributed into three groups according to their E/*e'* values (Fig. 1).

Table 1. Baseline clinical characteristics of the study group

	fQRS (+) (n=60)	fQRS (-) (n=40)	P
Age, years	51.1±8.3	48.5±8.2	NS
Men, n, %	39 (65%)	32 (80%)	NS
Body mass index, kg/m ²	26.2±3.1	25.6±2.9	NS
Smoker	26 (43.3%)	15 (37.5%)	NS
Systolic blood pressure, mmHg	119±13	117±13	NS
Diastolic blood pressure, mmHg	75.5±9.1	73.4±11.3	NS
Total cholesterol, mg/dL	195.1±26.1	182.1±24.7	NS
Low-density lipoprotein, mg/dL	117.5±23.5	112.5±28.6	NS
High-density lipoprotein, mg/dL	50.4±9.1	47.7±9.6	NS
Triglyceride, mg/dL	170.2±81.5	151.2±63.7	NS
Creatinine, mg/dL	0.90±0.21	0.88±0.16	NS
Fasting glucose, mg/dL	105.0±11.7	101.3±12.2	NS
Hemoglobin, gr/dL	12.9±1.7	12.7±1.5	NS
White blood cell count, 10 ³ /mm ³	7.42±1.51	7.50±1.35	NS

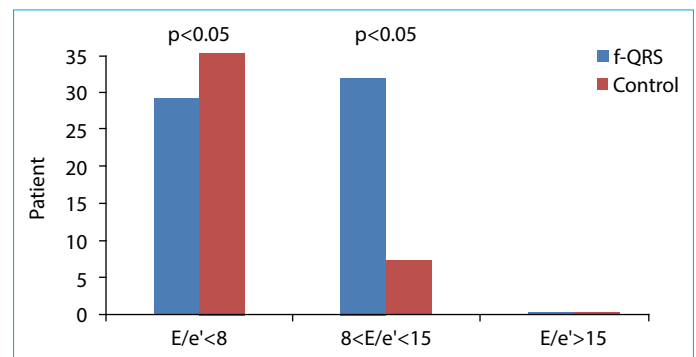
Table 2. Standard two-dimensional and Doppler echocardiographic measurements of the study subjects

Parameters	fQRS (+) n=60 (mean±SD)	fQRS (-) n=40 (mean±SD)	p
IVS (mm)	11.5±0.8	11.1±0.6	>0.05
PW (mm)	10.4±0.9	10.1±0.5	>0.05
LVEDD (mm)	45.3±2.7	43.2±2.5	<0.05≠
LVESD (mm)	30.3±2.1	30.4±1.7	>0.05
EF (%)	64.9±4.7	64.3±3.7	>0.05
LA (mm)	37.7±3.7	34.4±2.9	<0.05≠
RV (mm)	27.2±2.5	27.3±2.3	>0.05
E (cm/s)	0.64±0.17	0.67±0.15	>0.05
A (cm/s)	0.67±0.15	0.63±0.11	>0.05
E/A	0.99±0.2	1.1±0.3	>0.05
DT (ms)	184.2±31.8	163.3±29.2	>0.05
IVRT (ms)	88.7±12.4	80.4±12.4	>0.05
e' (cm/s)	0.07±0.11	0.10±0.02	<0.05*
a' (cm/s)	0.09±0.01	0.09±0.04	>0.05
e'/a'(average)	0.88±0.2	1.25±0.07	<0.05*
Septal e' (cm/s)	0.07±0.02	0.10±0.03	<0.05*
E/e' (septal)	9.1±2.9	6.8±2.08	<0.05*
E/e' (average)	8.1±2.09	6.4±1.5	<0.05*
MPI	0.54±0.08	0.49±0.06	>0.05

*Student t-test; p<0.05; ≠: Mann Whitney test; fQRS: fragmented QRS; IVS: interventricular septum; PW: posterior wall; LVEDD: left ventricular end-diastolic diameter; LVESD: left ventricular end-systolic diameter; EF: ejection fraction; LA: left atrium; RV: right ventricle; DT: deceleration time; IVRT: isovolumetric relaxation time; E/A: ratio of peak velocity of early mitral inflow to peak velocity of late mitral inflow; e': tissue Doppler mitral annular early wave velocity; E/e': ratio of peak velocity of early mitral inflow to mean value of peak early diastolic velocity calculated from septal: lateral, anterior, and inferior mitral annuli; MPI: myocardial performance index.

Discussion

CADs are among the leading causes of morbidity and mortality around the world. With regard to CAD, myocardial response may show itself as left ventricle diastolic dysfunction, diastolic heart failure, or systolic heart failure. It has been reported that changes in left ventricle diastolic functions in the case of CAD are associated with the effects of myocardial ischemia and fibrosis on diastolic hemodynamics and that clinically significant ventricular diastolic dysfunctions can develop even when non-ischemic CAD is present. However the pathogenesis of diastolic dysfunction in these patients has not been clarified yet.^[1,2] The diastolic relaxation of ventricles can deteriorate selectively, independent of systolic functions, due to the relaxation asynchronization between ischemic and normal myocardial segments in CAD patients.^[1,2] Left ventricular diastolic dysfunction can take an asymptomatic course for a long time during the transition period from subclinical myocardial damage to apparent heart failure. Asymptomatic

**Figure 1.** Distribution of groups according to E/e' (average) rate distinction.

diastolic dysfunction is generally more widely observed than the symptomatic disease. Echocardiography has a prominent place in the evaluation of these patients who are in the asymptomatic subclinical phase. Diastolic dysfunction that is detected with echocardiography can occur as an early finding of coronary artery disease. It has been reported that significant left ventricular diastolic dysfunction can develop even when silent myocardial ischemia is present.^[1,2] fQRS is a depolarization anomaly that indicates a conduction delay on standard surface ECGs with 12 leads. The formation of fQRS on an ECG is expressed with inhomogeneous activation of the ventricle due to myocardial fibrotic scar tissue. The cause of inhomogeneous myocardial depolarization is explained via QRS fragmentation, which is a result of the delay in potential action time due to a change in conduction path. fQRS is accepted as an underlying reason for the increased mortality and morbidity rates in ischemic/non-ischemic cardiomyopathy patients, arrhythmogenic right ventricle dysplasia/cardiomyopathy, amyloidosis, and Brugada syndrome.^[11,18-22] CAD plays an important role in the etiologies of infectious diseases, toxic agents, infiltrative diseases, radiation, endocrine diseases, autoimmune diseases, hypertension, and advanced-age myocardial fibrosis; this means that CAD is an important factor in the formation of fQRS.^[4-8] We minimized the risk factors of cardiac diastolic dysfunction in this study and recruited 60 patients with normal systolic function who had non-ischemic coronary artery disease in which angiographic coronary lesion did not cause ischemia less than 50% by vein diameter or less than 70% by area and who demonstrated fQRS on a normal systolic function surface ECG, as well as 40 control patients with the same demographic characteristics who did not show fQRS on a surface ECG. Patient tissue was taken from each of the four mitral annular segments (septal, anterior, posterior, lateral), Doppler echocardiography was carried out, and myocardial velocities were measured.

In this study, we found an apparent deterioration in the

transvalvular and tissue diastolic functions in the fQRS group compared to the control group. The segmental wall diastolic function disorders that we found on tissues were wider in the mitral annular septal plan compared to other areas. The averaged tissue Doppler parameters of the four segments and the transmitral velocities were significantly different in the fQRS group compared to the control group. The relationships of age, hypertension, obesity, and hyperlipidemia to diastolic functions are readily acknowledged; however, there was no statistical difference between the two groups based on comparison of these characteristics in this study.

Consequent to the controlled comparison performed on the two groups, we found that left ventricle diastole end diameters, left atrium diameters, conventional Doppler parameters, and tissue Doppler parameters were deteriorated in favor of fQRS. The reason the left atrium diameter is higher may be that the left atrium was under pressure in order to maintain cardiac output as a result of the decreased left ventricular compliance and hardening secondary to left ventricular diastolic dysfunction.^[23] However, we could not explain the high value of the left ventricular diastole end diameters ($p < 0.05$) compared to those of the control group. Nevertheless, we infer that age and systolic and diastolic blood pressure values may play a role in the high though not statistically significant-values of fQRS patients.

There were deteriorations in MPI, DT, and IVRT in favor of fQRS, but no statistical significance was found. The E/A ratio among the mitral flow parameters used to evaluate left ventricular diastolic dysfunction with conventional Doppler echocardiography, average e' among the tissue Doppler parameters, and average e'/a' ratios were found to be lower in the fQRS patients compared to the control group. Patients were divided into three groups according to their E/ e' rates: $E/e' < 8$; $E/e' = 8-15$; $E/e' > 15$. The mitral flow Doppler peak early diastolic flowrate, evaluated by conventional echocardiography, shows a good relationship with the left ventricular filling pressures compared to the peak early diastolic myocardial rate (E/ e') evaluated by the tissue Doppler imaging technique.^[24] $E/e' > 15$ was found to be highly specific in terms of increased left atrial pressure, while $E/e' < 8$ was considered highly sensitive in terms of normal left atrial pressure.^[25]

Because the combination of mitral valve and mitral flow rate curves and the tissue Doppler echocardiography better reflects left ventricular filling pressure, we determined that there was an apparent increase in favor of fQRS in E/average e' ($8 < E/e' < 15$), which reflects the ratio of the left ventricular end pressure and valve rate to the combined transmitral flow rate. As discussed above, fQRS is a direct in-

dication of myocardial fibrosis. Such regional myocardial fibrosis causes deterioration in myocardial relaxation during diastolic filling without affecting systolic functions and influences conventional Doppler results, in particular, at the tissue Doppler level. The most salient finding in the study is that IVRT and early fast filling is extended in patients whose ECGs indicate fQRS. According to these results, regional myocardial fibrosis causes decreased left ventricular absorption, decreased E velocity, and increased compensatory A velocity. As is the case with the patient group in this study, this pattern is defined as deteriorated relaxation or impaired relaxation type diastolic dysfunction. As a result, it is thought that the presence of fQRS on an ECG may be an early predictor of diastolic dysfunction.

Because a combination of mitral valve and mitral flow rate curves and tissue Doppler echocardiography ensured better estimation of left ventricular filling pressure, we can infer that it is of great importance to evaluate the echocardiographic diastolic functions of patients with fQRS on their ECGs and to assess each of the four left ventricular segments (anterior, posterior, lateral, septal) separately with tissue Doppler echocardiography. In addition to conventional parameters, tissue Doppler imaging is a valuable, noninvasive, and easily applicable method that can be utilized in the early detection of asymptomatic left ventricular diastolic dysfunction along with many other cardiovascular diseases.^[23,26]

This relation between fQRS and diastolic functions established in this study, as well as the ability to detect fQRS via ECG-a simple, cheap, and noninvasive test-and the formation mechanism of this pathological wave in coronary artery patients led us to consider the possibility of an indirect relationship between unstable plaques and fQRS. This study supports the benefits of early medical treatment of coronary artery patients with whose ECG indicates fQRS and whose risk factors are decreased, as protective cardiology principally aims to prevent the initial development of atherosclerotic plaque if possible and to prevent cardiovascular results by stabilizing such plaques if the former is not possible. The present study is limited, and thus further detailed studies with a wider population are necessary to illuminate this issue. We did not measure pulmonary vein flows due to difficulties during its measurement.

Conclusion

According to the results of this study, left ventricular diastolic function deteriorates both locally and globally, and such deterioration shows itself more apparently on the tissue surface if fQRS is found on a surface ECG. Consequently, the presence of fQRS found on a resting surface ECG can

be an early predictor of diastolic dysfunction in coronary artery patients with non-critical stenosis whose normal systolic function is proven by coronary angiography. The relation of fQRS to myocardial fibrosis is an acknowledged phenomenon. However, further detailed studies should be carried out to clarify the relationship between fibrosis and CAD without critical stenosis in patients whose risk factors for myocardial fibrosis formation are eliminated.

Disclosures

Ethics Committee Approval: The study was approved by the Local Ethics Committee.

Peer-review: Externally peer-reviewed.

Conflict of Interest: None declared.

Authorship Contributions: Concept – F.S., M.M., S.Y., O.G.; Design – F.S., M.M.; Supervision – F.S., M.M., O.G.; Materials – F.S., S.Y., M.A.; Data collection &/or processing – F.S., M.M., S.Y., M.A.; Analysis and/or interpretation – F.S., M.M.; Literature search – F.S., M.A.; Writing – F.S., M.M., S.Y.; Critical review – M.M., O.G.

References

- Galderisi M. Diastolic dysfunction and diastolic heart failure: diagnostic, prognostic and therapeutic aspects. *Cardiovasc Ultrasound* 2005;3:9. [CrossRef]
- García-Fernández MA, Azevedo J, Moreno M, Bermejo J, Pérez-Castellano N, Puerta P, et al. Regional diastolic function in ischaemic heart disease using pulsed wave Doppler tissue imaging. *Eur Heart J* 1999;20:496–505. [CrossRef]
- Topol EJ, Yadav JS. Recognition of the importance of embolization in atherosclerotic vascular disease. *Circulation* 2000;101:570–80. [CrossRef]
- Wang DD, Buerkel DM, Corbett JR, Gurm HS. Fragmented QRS complex has poor sensitivity in detecting myocardial scar. *Ann Noninvasive Electrocardiol* 2010;15:308–14. [CrossRef]
- Das MK, Suradi H, Maskoun W, Michael MA, Shen C, Peng J, et al. Fragmented wide QRS on a 12-lead ECG: a sign of myocardial scar and poor prognosis. *Circ Arrhythm Electrophysiol* 2008;1:258–68. [CrossRef]
- Carey MG, Luisi AJ Jr, Baldwa S, Al-Zaiti S, Veneziano MJ, deKemp RA, et al. The Selvester QRS Score is more accurate than Q waves and fragmented QRS complexes using the Mason-Likar configuration in estimating infarct volume in patients with ischemic cardiomyopathy. *J Electrocardiol* 2010;43:318–25. [CrossRef]
- Das MK, Saha C, El Masry H, Peng J, Dandamudi G, Mahenthiran J, et al. Fragmented QRS on a 12-lead ECG: a predictor of mortality and cardiac events in patients with coronary artery disease. *Heart Rhythm* 2007;4:1385–92. [CrossRef]
- Das MK, Michael MA, Suradi H, Peng J, Sinha A, Shen C, et al. Usefulness of fragmented QRS on a 12-lead electrocardiogram in acute coronary syndrome for predicting mortality. *Am J Cardiol* 2009;104:1631–7. [CrossRef]
- Akgul O, Uyarel H, Pusuroglu H, Surgit O, Turen S, Erturk M, et al. Predictive value of a fragmented QRS complex in patients undergoing primary angioplasty for ST elevation myocardial infarction. *Ann Noninvasive Electrocardiol* 2015;20:263–72.
- Pei J, Li N, Gao Y, Wang Z, Li X, Zhang Y, et al. The J wave and fragmented QRS complexes in inferior leads associated with sudden cardiac death in patients with chronic heart failure. *Europace* 2012;14:1180–7. [CrossRef]
- Sha J, Zhang S, Tang M, Chen K, Zhao X, Wang F. Fragmented QRS is associated with all-cause mortality and ventricular arrhythmias in patient with idiopathic dilated cardiomyopathy. *Ann Noninvasive Electrocardiol* 2011;16:270–5. [CrossRef]
- Jain R, Singh R, Yamini S, Das MK. Fragmented ECG as a risk marker in cardiovascular diseases. *Curr Cardiol Rev* 2014;10:277–86. [CrossRef]
- Bayramoğlu A, Taşolar H, Bektaş O, Yaman M, Kaya Y, Özbilen M, et al. Association between metabolic syndrome and fragmented QRS complexes: Speckle tracking echocardiography study. *J Electrocardiol* 2017;50:889–93. [CrossRef]
- Tanriverdi Z, Eyuboglu M, Bingol Tanriverdi T, Nurdag A, Demirbag R. The relationship between fragmented QRS and non-dipper status in hypertensive patients without left ventricular hypertrophy. *Clin Exp Hypertens* 2017;39:680–4.
- Das MK, Khan B, Jacob S, Kumar A, Mahenthiran J. Significance of a fragmented QRS complex versus a Q wave in patients with coronary artery disease. *Circulation* 2006;113:2495–501.
- Reiber JH, Serruys PW, Kooijman CJ, Wijns W, Slager CJ, Gerbrands JJ, et al. Assessment of short-, medium-, and long-term variations in arterial dimensions from computer-assisted quantitation of coronary cineangiograms. *Circulation* 1985;71:280–8. [CrossRef]
- Tei C. New non-invasive index for combined systolic and diastolic ventricular function. *J Cardiol* 1995;26:135–6.
- Das MK, Maskoun W, Shen C, Michael MA, Suradi H, Desai M, et al. Fragmented QRS on twelve-lead electrocardiogram predicts arrhythmic events in patients with ischemic and nonischemic cardiomyopathy. *Heart Rhythm* 2010;7:74–80. [CrossRef]
- Brenyo A, Pietrasik G, Barsheshet A, Huang DT, Polonsky B, McNitt S, et al. QRS fragmentation and the risk of sudden cardiac death in MADIT II. *J Cardiovasc Electrophysiol* 2012;23:1343–8. [CrossRef]
- Cheema A, Khalid A, Wimmer A, Bartone C, Chow T, Spertus JA, et al. Fragmented QRS and mortality risk in patients with left ventricular dysfunction. *Circ Arrhythm Electrophysiol* 2010;3:339–44. [CrossRef]
- Rattanawong P, Riangwiwat T, Prasitlumkum N, Limpruttidham N, Kanjanahattakij N, Chongsathidkiet P, et al. Baseline fragmented QRS increases the risk of major arrhythmic events in Brugada syndrome: Systematic review and meta-analysis.

- Ann Noninvasive Electrocardiol 2018;23:e12507. [\[CrossRef\]](#)
22. Peters S, Trümmel M, Koehler B. QRS fragmentation in standard ECG as a diagnostic marker of arrhythmogenic right ventricular dysplasia-cardiomyopathy. *Heart Rhythm* 2008;5:1417–21.
 23. Nishimura RA, Tajik AJ. Evaluation of diastolic filling of left ventricle in health and disease: Doppler echocardiography is the clinician's Rosetta Stone. *J Am Coll Cardiol* 1997;30:8–18.
 24. Ommen SR, Nishimura RA, Appleton CP, Miller FA, Oh JK, Redfield MM, et al. Clinical utility of Doppler echocardiography and tissue Doppler imaging in the estimation of left ventricular filling pressures: A comparative simultaneous Doppler-catheterization study. *Circulation* 2000;102:1788–94. [\[CrossRef\]](#)
 25. Nagueh SF, Middleton KJ, Kopelen HA, Zoghbi WA, Quiñones MA. Doppler tissue imaging: a noninvasive technique for evaluation of left ventricular relaxation and estimation of filling pressures. *J Am Coll Cardiol* 1997;30:1527–33. [\[CrossRef\]](#)
 26. Alam M, Wardell J, Andersson E, Samad BA, Nordlander R. Characteristics of mitral and tricuspid annular velocities determined by pulsed wave Doppler tissue imaging in healthy subjects. *J Am Soc Echocardiogr* 1999;12:618–28. [\[CrossRef\]](#)